

CASE REPORT

Bilateral osseous stenosis of the internal auditory canal: case report

A proposito di un caso di stenosi bilaterale ossea del condotto uditivo interno

A. CIORBA, C. AIMONI, C. BIANCHINI, M. BORRELLI¹, F. CALZOLARI¹, A. MARTINI

Audiology Department, ¹ Neuroradiology Department, University Hospital of Ferrara, Italy

SUMMARY

Osteomas as well as exostoses of the internal auditory canal are rare, benign, usually slow-growing lesions. The most common localizations of these temporal bone lesions are the mastoid cortex and the external auditory canal. A rare case is reported of bilateral osseous stenosis of the internal auditory canal, in the absence of clinical (auditory, vestibular and facial nerve) symptoms. In the absence of auditory, vestibular and/or facial nerve symptoms, long-term follow-up should be assessed; surgical intervention may be warranted only if symptoms are present.

KEY WORDS: Internal auditory canal • Osteomas • Exostosis • Skull base • Imaging

RIASSUNTO

Gli osteomi e le esostosi del condotto uditivo interno rappresentano una condizione patologica di raro riscontro, benigna e di solito caratterizzata da un lento accrescimento. Le localizzazioni più frequenti di tali lesioni dell'osso temporale sono la corticale mastoidea e il condotto uditivo esterno. Gli autori riportano un raro caso di stenosi bilaterale ossea del condotto uditivo interno, in assenza di sintomi o segni audiologici. In assenza di sintomatologia uditiva, vestibolare o deficit del facciale, è necessario sottoporre il paziente a follow-up a lungo termine, mentre l'opzione chirurgica è da considerarsi solo qualora vi siano manifestazioni cliniche importanti.

PAROLE CHIAVE: Condotto uditivo interno • Osteomi • Esostosi • Base cranio • Neuroradiologia

Acta Otorhinolaryngol Ital 2011;31:177-180

Introduction

Osteomas and exostoses have distinct clinical and histopathologic features¹. Osteomas are usually solitary, pedunculated, bony growths attached to the tympano-squamous or tympano-mastoid suture line, characterized histologically by an internal structure of abundant discrete fibrovascular channels surrounded by irregularly oriented lamellated bone. Exostoses are usually multiple, bilaterally symmetrical, broad based elevations of bone involving the tympanic bone^{1,2}.

Osteomas are uncommon, slow-growing lesions that can develop in the cranium. They represent a localized hamartomatous proliferation of a usually dense, although otherwise normal, intra-membranous bone, while exostoses are histologically composed of parallel layers of sub-epithelial bone¹.

The most common localizations of temporal bone osteomas are the mastoid cortex and the external auditory canal¹. These benign neoplasms have also been described within the mastoid air cells, middle ear, but rarely in the internal auditory canal (IAC)^{1,3}. Exostoses are observed in the external auditory canal even four times more frequent-

ly than osteomas¹, but have very rarely been described in the tympanic cavity or in the internal auditory canal^{1,4}.

Case report

B.P. is a 32-year-old caucasian male, addressed to the Audiology Department of the University Hospital of Ferrara due to the incidental finding of bilateral stenosis of the internal auditory canals.

His past medical history was unremarkable, with the exception of an acute episode of "vertical diplopia" which occurred 6 months prior to our evaluation. He was examined in the Emergency Room by the neurologist and the ophthalmologist; both evaluations resulted negative, and cerebral magnetic resonance imaging (MRI) scans were ordered. The diplopia spontaneously recovered; MRI were normal except for the incidental report of bilateral stenosis of the internal auditory canals. At this point, a computed tomography (CT) scan was performed in order to complete the internal auditory canal evaluation (Fig. 1A, B).

Upon examination, there was no history of hearing loss, vertigo, tinnitus or facial nerve weakness. Moreover, there

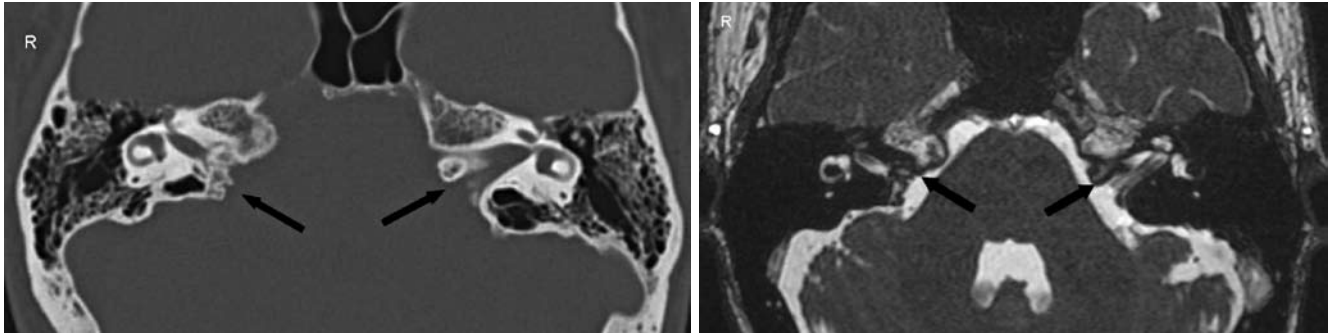


Fig. 1. A. CT Scan, axial image. Bilateral stenoses of internal auditory canal (black arrows). B. T2-weighted MRI axial image showing bilateral stenosis of the internal auditory canal (black arrows).

was no history or evidence of other bone disease (such as hereditary multiple exostoses HME).

The ENT status and particularly the microscopical examination resulted normal. Pure tone audiograms showed a bilateral normal hearing; vestibular testing was normal (Fig. 2A, B) and there were no signs of facial nerve weakness. Also the auditory brainstem responses (ABR) resulted normal in terms of latency values as well as latency intervals (Fig. 3).

So far, after 12 months of close follow-up, the patient has no clinical signs of auditory vestibular and/or facial nerve disease.

Discussion and Conclusions

Osteomas, as well as exostoses of the internal auditory canal, are rare, benign, usually slow-growing lesions. Reported aetiological factors contributing to the formation of these lesions include injury, inflammation, developmental disorders, and genetic defects⁵. These entities are usually asymptomatic, as in the case presented here, but might cause symptoms attributable to a local compressive effect, depending on their specific location.

As far as concerns their exact position and dimensions, internal auditory canal lesions might manifest as sensorineural hearing loss, vertigo, tinnitus, or even cause brainstem compression^{2,6,7}, thus mimicking symptoms of vestibular schwannomas^{7,8}. Bilateral internal auditory canal lesions are typical of neurofibromatosis type 2 and are usually vestibular or facial nerve schwannomas⁹.

Although the presence of internal auditory canal narrowing upon MRI scan might aid in its detection, the diagnosis of internal auditory canal osteoma or exostosis relies entirely upon high-resolution CT scanning, which demonstrates well demarcated, dense bone outgrowth⁶. A stenosis of the internal auditory canal may be seen as a congenital anomaly in conjunction with eighth-nerve aplasia or in disorders of bone, including osteopetrosis, Paget disease, otosclerosis, or fibrous dysplasia^{2,10}.

The present report refers to a rare case of bilateral stenosis of the internal auditory canal, in the absence of clinical (auditory, vestibular and/or facial nerve) symptoms. The vertical diplopia was judged as an occasional event, and, therefore, not related to the internal auditory canal findings, as both the neurological and the ophthalmological evaluation, as well as the cerebral MRI were negative.

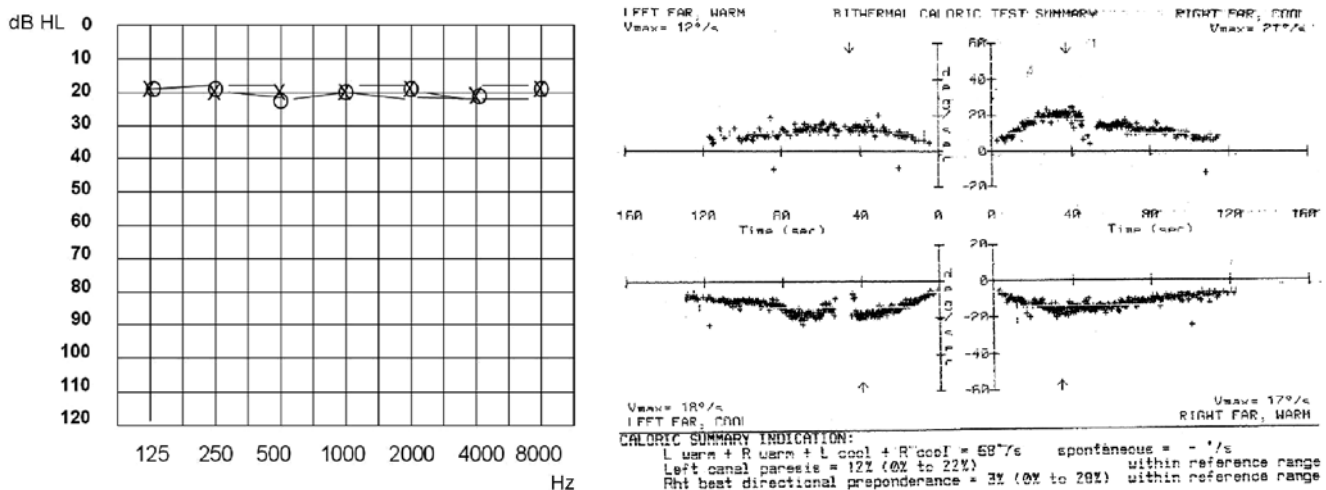


Fig. 2. Audiogram (A) and vestibular caloric tests (B) showing a bilateral normal hearing and vestibular function.

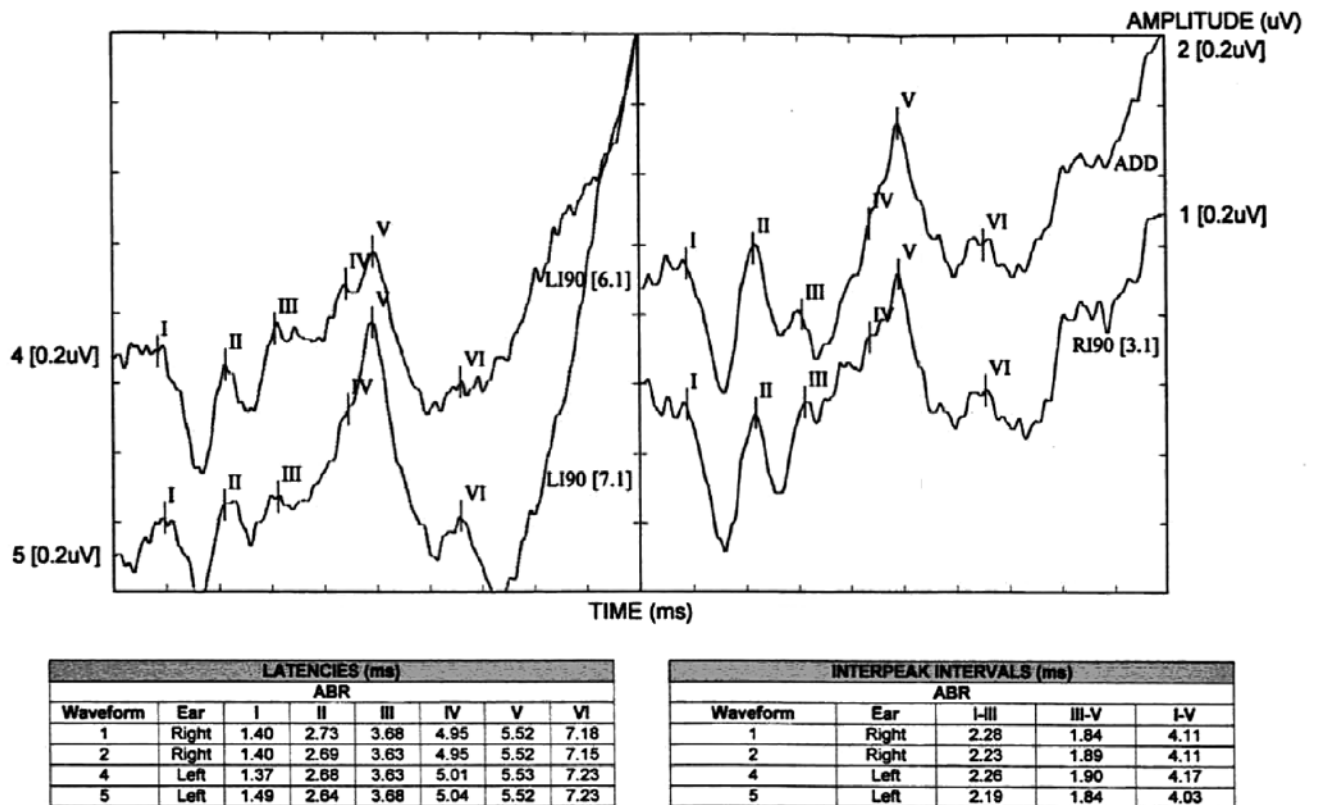


Fig. 3. At the A.B.R., latency values as well as latency intervals were found to be normal.

Table I. Internal auditory canal bony lesions reported in the literature, available through a "Pubmed database" search, performed in June 2010.

Authors and Year	IAC lesion	Clinical evidence*	Treatment
Gerganov et al., 2008	Osteoma	Symptomatic	Surgery
Arnoldner et al., 2006	Exostosis	Symptomatic	No surgical treatment
Kovacic et al., 2001	Osteoma	Asymptomatic	No surgical treatment
Davis et al., 2000	Osteoma	Symptomatic	Surgery
Vrabec et al., 2000	Osteoma	Symptomatic	Surgery
Torres-Valenzuela, 1998	Osteoma	N/A	N/A
Boedts et al., 1997	Osteoma	Symptomatic	No surgical treatment
Wright et al., 1996	Osteoma	Symptomatic	Surgery
Coakley et al., 1996	Osteoma	Symptomatic	Surgery
Clerico et al., 1994	Osteoma	Symptomatic	Surgery
Ramsey & Brackman, 1994	N/A	Symptomatic	Surgery
Estrem et al., 1993	Osteoma	Symptomatic	Surgery
Singh et al., 1992	Osteoma	N/A	N/A
Doan, 1988	N/A	Symptomatic	Surgery
Navrátil, 1988	Exostosis	Symptomatic	Surgery
Beale et al., 1984	Osteoma	N/A	N/A
Smelt 1984	Exostosis	Asymptomatic	No surgical treatment
Roberto et al, 1979	N/A	Symptomatic	Surgery

* Symptomatic has been used to define those cases affected by one of the following: hearing loss, vertigo, or facial nerve palsy. N/A: data not available. Authors listed in Table can be found in Reference section^{2,5-9,11,12-21}.

Moreover, no correlations have been reported, so far, in the literature, between internal auditory canal stenosis and the occurrence of diplopia.

It has not been possible to definitely differentiate between osteoma and exostosis, on the basis of the neuroradiological features (both CT and MRI scans); the fact that the lesion is bilateral argues in favour of an exostosis, whilst the CT dishomogeneous density advocates an osteoma feature. Even if the neuroradiological characteristics of the case presented are not unlike those of osteomas, previously described, and also histologically defined in other clinical reports^{2,9}, clearly only the histological features could differentiate between these two entities. Nonetheless, most of the internal auditory canal lesions reported in the literature are based on the radiological appearance alone^{2,6,11}.

The natural evolution of osteomas and/or exostoses is unpredictable; however, they usually grow slowly and remain stable for many years. Due to the paucity of reported

cases of osteoma and exostoses of the internal auditory canal, as well as the variability of the clinical course and treatment, it is impossible to draw any definite conclusions regarding the natural history of this lesion and the appropriateness of the therapeutic approach (please refer to Table I for a list of bony internal auditory canal lesions reported in the literature, so far)².

In conclusion, it is necessary to accept that, today, a correct assessment of bony internal auditory canal lesion is necessary using both, MRI and CT scans. As in our case, clinically asymptomatic lesions should be assessed by regular clinical audiovestibular examinations and eventually with regular CT monitoring. Surgery is the reported treatment of choice only in the presence of symptomatic or enlarging internal auditory canal exostoses/osteomas⁹. Hopefully, in the near future, as more case reports with longer follow-up become available, it will be possible to better understand the natural history of these lesions and, therefore, to standardize the clinical treatment.

References

- ¹ Nager GT. *Pathology of the ear and temporal bone*. Baltimore, MD: Williams and Wilkins 1993; p. 483-512.
- ² Vrabec JT, Lambert PR, Chaljub G. *Osteoma of the internal auditory canal*. Arch Otolaryngol Head Neck Surg 2000;126:895-8.
- ³ Schuknecht HF. *Pathology of the ear*. Philadelphia, PA, USA: Lea and Febiger 1993; p. 476.
- ⁴ Arnoldner C, Stöver T, Bartling SH, et al. *Exostosis of the internal auditory canal in a patient with myotonic dystrophy*. Laryngorhinootologie 2006;85:755-9.
- ⁵ Clerico DM, Jahn AF, Fontanella S. *Osteoma of the internal auditory canal. Case report and literature review*. Ann Otol Rhinol Laryngol 1994;103:619-23.
- ⁶ Boedts M, Hermans R, Feenstra L. *Osteoma of the internal auditory canal*. Acta Otorhinolaryngol Belg 1997;51:191-3.
- ⁷ Singh V, Annis JA, Todd GB. *Osteoma of the internal auditory canal presenting with sudden unilateral hearing loss*. J Laryngol Otol 1992;106:905-7.
- ⁸ Ramsay HA, Brackmann DE. *Osteoma of the internal auditory canal. A case report*. Arch Otolaryngol Head Neck Surg 1994;120:207-8.
- ⁹ Gerganov VM, Samii A, Paterno V, et al. *Bilateral osteomas arising from the internal auditory canal: case report*. Neurosurgery 2008;62:528-9.
- ¹⁰ Hamersma H. *Osteopetrosis (marble bone disease) of the temporal bone*. Laryngoscope 1970;80:1518-39.
- ¹¹ Beale DJ, Phelps PD. *Osteomas of the temporal bone: a report of three cases*. Clin Radiol 1987;38:67-9.
- ¹² Kovacic J, Subarić M, Lajtman Z, et al. *Osteoma of the internal auditory canal*. Acta Med Croatica 2001;55:215-8.
- ¹³ Davis TC, Thedinger BA, Greene GM. *Osteomas of the internal auditory canal: a report of two cases*. Am J Otol 2000;21:852-6.
- ¹⁴ Torres-Valenzuela A. *Osteoma of the internal auditory canal. Presentation of a case and review of the bibliography*. Gac Med Mex 1998;134:355-7.
- ¹⁵ Wright A, Corbridge R, Bradford R. *Osteoma of the internal auditory canal*. Br J Neurosurg 1996;10:503-6.
- ¹⁶ Coakley DJ, Turner J, Fagan PA. *Osteoma of the internal auditory canal: case report*. J Laryngol Otol 1996;110:158-60.
- ¹⁷ Estrem SA, Vessely MB, Oro JJ. *Osteoma of the internal auditory canal*. Otolaryngol Head Neck Surg 1993;108:293-7.
- ¹⁸ Doan HT, Powell JS. *Exostosis of the internal auditory canal*. J Laryngol Otol 1988;102:173-5.
- ¹⁹ Navrátil J. *Transtemporal neurectomy of the vestibular nerve for vertigo caused by exostosis of the internal auditory canal*. Cesk Otolaryngol 1988;37:106-8.
- ²⁰ Smelt GJ. *Exostoses of the internal auditory canal*. J Laryngol Otol 1984;98:347-50.
- ²¹ Roberto M, Ettore GC, Iurato S. *Stenosis of the internal auditory canal*. J Laryngol Otol 1979;93:1211-6.

Received: March 15, 2010 - Accepted: June 21, 2010 - EPUB December 29, 2010

Address for correspondence: Dr. A. Ciorba, U.O. di Audiologia, Università di Ferrara, c.so Giovecca 203, 44100 Ferrara, Italy. Fax: +39 0532 236887. E-mail: andrea.ciorba@unife.it